ResearchGate

See discussions, stats, and author profiles for this publication at: https://www.researchgate.net/publication/327798547

Ultrasound-Guided Percutaneous Cryoneurolysis for Postoperative Analgesia After Limb Amputation: A Case Series

Article *in* A & A Practice · September 2018

DOI: 10.1213/XAA.0000000000000893

CITATIONS
14

READS
247

4 authors, including:

Andrea M Trescot
Pain and Headache Center
148 PUBLICATIONS **5,928** CITATIONS

SEE PROFILE

Brian M Ilfeld
University of California, San Diego
229 PUBLICATIONS **7,568** CITATIONS

SEE PROFILE

Some of the authors of this publication are also working on these related projects:

Project Hydrodissection and Neural Regenerative Strategies View project

Project Clinical Outcomes of Epidural Steroid Injections View project

All content following this page was uploaded by Andrea M Trescot on 24 September 2018.

The user has requested enhancement of the downloaded file.

Ultrasound-Guided Percutaneous Cryoneurolysis for Acute Pain Management: A Case Report

Rodney A. Gabriel, MD,* John J. Finneran, MD,* Deepa Asokan, MD,* Andrea M. Trescot, MD,† NavParkash S. Sandhu, MD, MS,* and Brian M. Ilfeld, MD, MS (Clinical Investigation)*

We report 3 different cases in which ultrasound-guided percutaneous cryoneurolysis was performed to treat acute pain: 1 patient with refractory incisional pain after percutaneous nephrolithotomy; 1 patient with burns to the foot; and 1 patient with pain from iliac crest grafting. Acute pain associated with surgery or injury is a challenge to treat with local anesthetic-based regional anesthesia techniques when the anticipated pain duration exceeds a few days. Cryoneurolysis is an alternative analgesic method that utilizes extremely cold temperatures to reversibly ablate peripheral nerves and is potentially a novel method for acute pain management. (A&A Case Reports. 2017;XXX:00–00.)

Tissue injury that results in moderate-to-severe acute pain lasting more than a few days may be a challenge to treat with local anesthetic-based regional anesthesia techniques. Continuous peripheral nerve blocks extend the duration of analgesia beyond that of single-injection nerve blocks, but their effectiveness is limited by the risks of catheter infection, catheter migration and leakage, and infusion pump malfunction, and by the burden of carrying an infusion pump and local anesthetic reservoir bag.[1]

Cryoneurolysis is an alternative analgesic modality that utilizes extremely cold temperatures to reversibly ablate peripheral nerves.[2] This technique has predominantly been used to treat chronic pain, although percutaneous probes, ultrasound guidance, and the recent development of a handheld cryoneurolysis device now enable a wider range of clinical applications.[3] We describe 3 patients who received cryoneurolysis that provided multiple weeks of analgesia for 3 different acute pain indications. The university institutional review board (University of California, San Diego) waives any review requirements for case reports or short series; but all patients provided written consent for publication and for the procedure.

CASE DESCRIPTIONS

Ultrasound-guided percutaneous cryoneurolysis was performed with a handheld cryoneurolysis device (Iovera; Myoscience, Fremont, CA) on all 3 patients. A portable ultrasound (SonoSite M-Turbo, Bothell, WA) with either a 13 to 6–MHz linear ultrasound transducer (HFL38; SonoSite, Bothell, WA) or a 8 to 5–MHz curvilinear ultrasound transducer (C11n; SonoSite, Bothell, WA) was used. All procedures utilizing ultrasound guidance were performed with a 5.5-cm cryoablation probe (Figure 1) introduced through a 16-or 20-g angiocatheter. Before all procedures, standard American Society of Anesthesiologists monitors were used, and the block site was prepared with chlorhexidine gluconate. Lidocaine 1% was used for skin analgesia. The short-axis view of the target nerve was visualized with ultrasound, and an in-plane approach was performed. First, the target nerve was treated with 2% lidocaine (1:400,000 epinephrine) to demonstrate that the nerve block adequately treated the pain. After 5 minutes, if the patient reported adequate pain relief and felt that the resulting numbness sensation was tolerable, cryoneurolysis was performed. A 16- or 20-g angiocatheter needle was introduced until the distal tip was about 1 to 3 cm from the nerve. At that point, the needle was disengaged from the angiocatheter. The cryoneurolysis probe was then introduced through the angiocatheter. Three or four 2-minute cryoablation cycles separated by 1-minute thaw periods were applied to each nerve in slightly different locations.

Case 1: Percutaneous Nephrolithotomy

The patient was a 51-year-old man with a history of human immunodeficiency virus, congenital anomaly of the kidney, and recurrent nephrolithiasis requiring multiple urological procedures who underwent a percutaneous nephrolithotomy with stent placement and subsequent stent removal a few days afterward. The patient had inadequate pain relief in the recovery room despite escalating doses of intravenous opioids. His continued complaint of sharp pain with a score of 10 on a 0 to 10 numeric rating scale (NRS) located at the incision necessitated hospital admission. His pain was refractory to escalating doses of intravenous morphine, gabapentin, acetaminophen, oxycodone, and ketorolac. A single-injection ultrasound-guided T11 intercostal block (parasagittal approach) was performed with 10 mL of 4% lidocaine (1:400,000 epinephrine; in-plane approach). This initially relieved all of the patient's pain, but it recurred upon block resolution after 6 hours. To extend the intercostal nerve-related analgesia, cryoneurolysis was administered the following day. The cryo device was used to apply 3 freeze–thaw cycles anterior, caudal, and superficial to the T11 intercostal nerve (Figure 2). Within 10 minutes, the patient's incisional pain resolved. He described a continuing "deep kidney" dull ache with an NRS pain score up to 2 that required no other analgesics for the remainder of the day.

From the *Department of Anesthesiology, University of California San Diego, La Jolla, California; and the †Alaska Pain Management Center, Eagle River, Alaska.

Accepted for publication February 17, 2017.

Funding: Myoscience (Fremont, CA) provided the cryoneurolysis device and probes used for these cases.

Conflicts of Interest: See Disclosures at the end of the article.

Address correspondence to Rodney A. Gabriel, MD, University of California San Diego, 9500 Gilman Dr, MC 0881, La Jolla, CA 92093-0881. Address e-mail to ragabriel@ucsd.edu.

Copyright © 2017 International Anesthesia Research Society
DOI: 10.1213/XAA.0000000000000546

Copyright © 2017 International Anesthesia Research Society. Unauthorized reproduction of this article is prohibited.

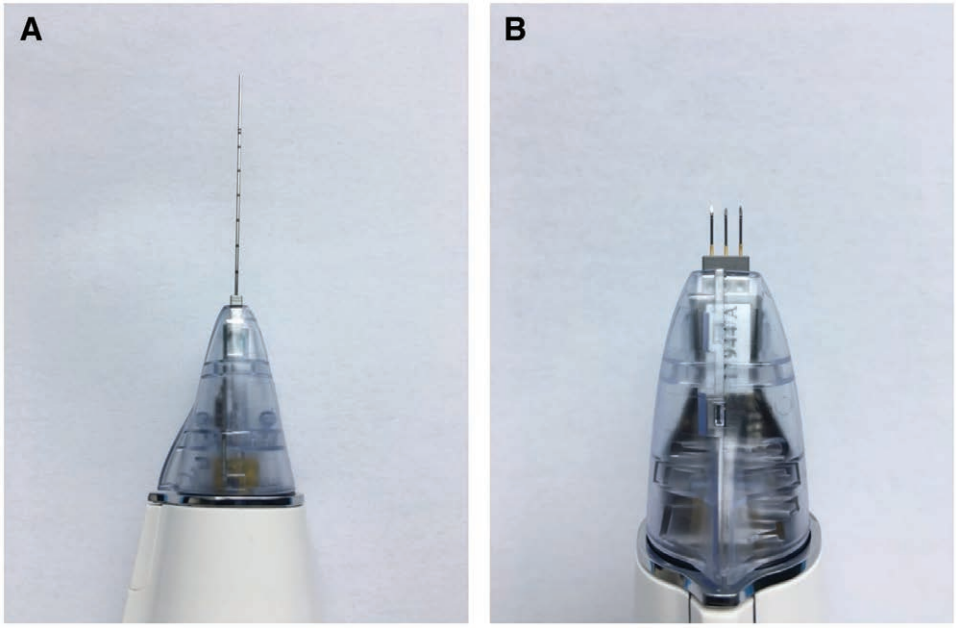

Figure 1. A portable cryoneurolytic device (Iovera Focused Cold Therapy, Myoscience, Freemont, CA) attached to a 5.5-cm probe (A) and 3-probe tip (B) (6.9 mm each tip) for cryoneurolysis of superficial nerves.

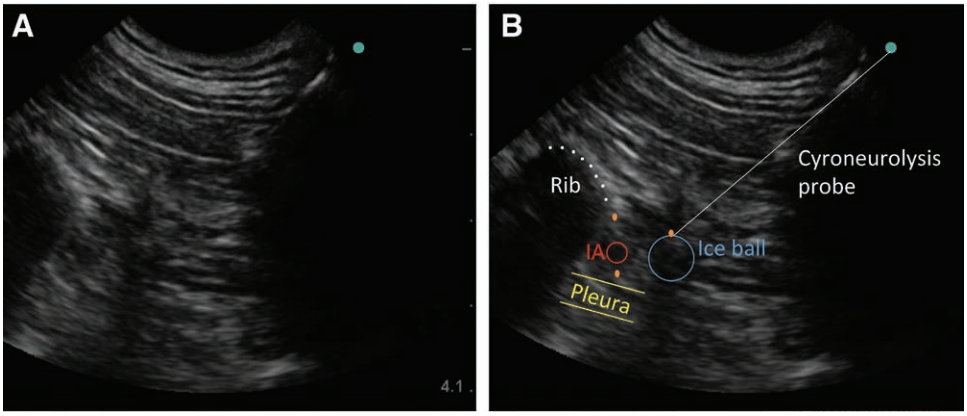

Figure 2. A, A parasagittal ultrasound view of T11 intercostal nerve where cryoneurolysis was performed. B, Same image in A, but with labels. Blue circle indicates area of ice ball created from cryoneurolysis; cyan dot, caudal to the nerve; IA, intercostal artery; orange dots, 3 dots indicating where cryoneurolysis freeze–warm cycles performed relative to intercostal nerve; white line, trajectory of cryoneurolysis probe.

He was discharged home the following day, and the analgesic effect lasted 15 days, after which his incisional pain returned but was at a much lower—and tolerable—level.

Case 2: Burn Injury to Foot

The patient was a 46-year-old woman with insulin-dependent diabetes, peripheral neuropathy, and depression, who initially presented with 0.5% total burn surface area to the right foot due to scald injury from boiling water. The burns were located in the dorsal and plantar aspects of the first to third toes. She reported an NRS pain score of 10 throughout the injured area. Initially, a sciatic nerve block with perineural catheter was placed to aid in analgesia and help the patient tolerate wound dressing changes. The catheter eventually dislodged after 7 days, but was not replaced due to the risk of infection since the patient developed osteomyelitis of the toes (presumably unrelated to the initial perineural catheter). For the next few days, her pain was inadequately controlled with pregabalin, oxycodone, acetaminophen, and intravenous hydromorphone. Four freeze–thaw cryoneurolysis cycles were administered deep, medial, lateral, and finally superficial to the posterior tibial nerve. To target the superficial peroneal nerve, cryoneurolysis was applied blindly along a subcutaneous treatment line between the lateral malleolus and the extensor halluces longus tendon using a device tip with three 6.9-mm probes. A single 2-minute cryoneurolysis application was used at each location along the treatment line. Because multiple attempts to block the deep peroneal nerve by applying local anesthetic next to the anterior tibial artery provided inadequate analgesia, it was decided to forego cryoneurolysis for this nerve. Subsequently, she denied any pain in the distribution of the plantar and superficial peroneal nerve. Her NRS pain score was consistently and exclusively 3 to 5 in the deep peroneal nerve distribution. After 14 days, her pain returned but at a more tolerable level.

Case 3: Iliac Crest Bone Grafting

This patient was a 56-year-old woman with a history of mild obstructive sleep apnea who presented with a comminuted fracture of the proximal humerus with nonunion and underwent right total shoulder arthroplasty and iliac crest bone grafting. The patient received a preoperative interscalene peripheral nerve block with a perineural catheter

Copyright © 2017 International Anesthesia Research Society. Unauthorized reproduction of this article is prohibited.

and received general anesthesia for the shoulder surgery. Postoperatively, she reported no significant shoulder pain, but she did complain of severe pain (NRS pain score of 8–9) in the right anterolateral hip where the iliac crest bone graft had been performed. Pain was refractory to escalating doses of intravenous hydromorphone and oxycodone over 48 hours. A nerve block with lidocaine to the T12 subcostal nerve did not improve pain, but one to the T11 intercostal nerve successfully attenuated pain. The T11 block was performed via a parasagittal approach, and the needle was inserted in-plane. Because pain relief was adequate upon local anesthetic delivery to T11, 3 freeze–thaw cryoneurolysis cycles were applied anterior, caudal, and superficial to the T11 intercostal nerve. For multiple weeks, the patient consistently reported an NRS pain score of 0 to 3 in the hip.

DISCUSSION

Local anesthesia-based regional anesthesia has been applied to a variety of acute pain states, especially in the perioperative patient population. However, duration of action is its major limitation. In this case series, we successfully applied cryoneurolysis to provide analgesia of several weeks duration in 3 different acute pain scenarios. There were no residual sensory or motor deficits, and no adverse events occurred that were associated with cryoneurolysis.

Cryoanalgesia has been used for decades for pain relief in the chronic pain population.[4] It was applied for postoperative analgesia in the 1980s by applying a cryoneurolysis probe directly to surgically exposed nerves.[5] A percutaneous approach[6] became possible with probes specifically designed for this use combined with ultrasound guidance.[7] The recent development of a handheld cryoneurolysis device has greatly improved applicability within a busy preoperative holding area or on hospital wards.[3]

Cryoneurolytic probes create an extremely cold temperature by passing gas at a high pressure—often nitrous oxide or carbon dioxide—down the shaft and through a small opening into a low-pressure closed tip. The drop in pressure and increase in volume from the shaft to the tip results in absorption of heat due to the Joule-Thomson effect.[2] The gas is subsequently evacuated through an internal tube within the shaft so that no gas remains within the patient. An ice ball forms at the tip of the probe due to the low temperature, inducing Wallerian degeneration distal to the point of ablation, causing a complete nerve block. Importantly, the endoneurium, perineurium, and epineurium remain intact, allowing neural regrowth distally from the point of ablation at 1 to 2 mm/d without the risk of neuroma formation.

The few relative or absolute contraindications to cryoneurolysis include bleeding disorders, infection, coagulopathy, cryoglobulinemia, cold urticaria, and Raynaud's syndrome. The risks include bleeding, localized infection, and nerve injury from physical trauma from the probe. Furthermore, if the ice ball comes into contact with the skin, risks include frostbite, depigmentation, and alopecia. Cryoneurolysis has been in clinical use for more than 5 decades with no published cases of permanent nerve injury or neuroma[8] and no evidence of permanent or long-term changes to nerve function following repeated treatments after full axon regeneration.[9,10] Although 2 investigations demonstrated a statistically significant increase in neuropathic pain in patients who received cryoneurolysis administered via the surgical incision,[11,12] the majority of trials reported no increased risk of persistent postoperative pain.[13–21] Given the aforementioned studies, we felt the risk of long-term sequelae of cryoanalgesia was low, and the benefit of long-term control of acute pain was high in our 3 patients. It is also important to weigh the risks of long-term numbness in the affected nerve. In this case series, none of the target nerves caused inappropriate disability.

Since this was a novel approach to acute pain using a tool that has been used for decades, patients received informed consent that involved discussion of: (1) theoretical nerve injury or persistent neuropathic pain (although previous studies largely have demonstrated lack of negative sequelae); and (2) unpredictable duration of action that may last from weeks to months. Before pursuing cryoanalgesia, a diagnostic block was initially performed so that the patient could preview the effects—emphasizing that while cryoanalgesia provides pain relief, it also causes numbness. Only when the patient demonstrated tolerability and acceptance to the diagnostic block was cryoneurolysis performed.

There are a multitude of unknown factors associated with cryoanalgesia in the setting of acute pain management. They include the optimal number of freeze cycles, duration of freeze and thaw cycles, and probe-to-nerve distance and orientation. A major limitation of cryoneurolysis is the complete sensory and motor block combined with the unpredictable duration. Some clinical circumstances benefit from such a block—such as those described in this report—but these are a minority of situations as a complete sensory/motor block obviously prohibits ambulation and self-protection of a limb. Lastly, although cryoneurolysis was not found to cause permanent impairment of motor nerves (even with repeated application) when used in laboratory animals[9,22] as well as human subjects,[10] additional investigation into its degree of blockade is warranted.

In summary, the positive outcomes in these 3 cases demonstrate the possibility of applying ultrasound-guided percutaneous cryoneurolysis to provide analgesia for acute pain states. However, application of this technique must be used with caution. Yet to be defined are the applicable acute pain indications. Ultimately, high-quality, randomized, controlled trials are required to ascertain the benefit-to-risk ratio and optimize procedure technique before widespread adoption of cryoneurolysis in acute pain management. ■

DISCLOSURES

Name: Rodney Gabriel, MD.
Contribution: This author helped plan the procedural protocol, perform procedures, and prepare the manuscript.
Conflicts of Interest: Dr Gabriel's institution has received products used in this report from Myoscience.
Name: John Finneran, MD.
Contribution: This author helped perform procedures and prepare the manuscript.
Conflicts of Interest: Dr Finneran's institution has received products used in this report from Myoscience.
Name: Deepa Asokan, MD.
Contribution: This author helped perform procedures and prepare the manuscript.
Conflicts of Interest: Dr Asokan's institution has received products used in this report from Myoscience.

Copyright © 2017 International Anesthesia Research Society. Unauthorized reproduction of this article is prohibited.

Name: Andrea Trescot, MD.
Contribution: This author helped plan the procedural protocol and prepare the manuscript.
Conflicts of Interest: Dr Trescot is an unpaid consultant to Epimed/Wallach, Metrum Cryoflex, and Myoscience, as well as a paid scientific advisor to Atricure.
Name: NavParkash Sandhu, MD.
Contribution: This author helped plan the procedural protocol, perform procedures, and prepare the manuscript.
Conflicts of Interest: Dr Sandhu's institution has received products used in this report from Myoscience.
Name: Brian Ilfeld, MD.
Contribution: This author helped plan the procedural protocol, perform procedures, and prepare the manuscript.
Conflicts of Interest: Dr Ilfeld's institution has received funding and products for his research from Myoscience, a manufacturer of a cryoneurolysis device (for studies other than the current report); infusion pump manufacturers Infutronics, Baxter Healthcare, Smiths Medical, and Summit Medical (a perineural catheter manufacturer); Teleflex Medical (a manufacturer of a peripheral nerve stimulation device); SPR Therapeutics; and 2 manufacturers of long-acting liposome bupivacaine formulation: Pacira Pharmaceuticals and Heron Pharmaceuticals. In addition, Dr Ilfeld has previously acted as a consultant to Pacira Pharmaceuticals.
This manuscript was handled by: Raymond C. Roy, MD.

REFERENCES

1. Ilfeld BM. Continuous peripheral nerve blocks: an update of the published evidence and comparison with novel, alternative analgesic modalities. *Anesth Analg*. 2017;124:308–335.
2. Trescot AM. Cryoanalgesia in interventional pain management. *Pain Physician*. 2003;6:345–360.
3. Ilfeld BM, Preciado J, Trescot AM. Novel cryoneurolysis device for the treatment of sensory and motor peripheral nerves. *Expert Rev Med Devices*. 2016;13:713–725.
4. Gage AA. History of cryosurgery. *Semin Surg Oncol*. 1998;14:99–109.
5. Khanbhai M, Yap KH, Mohamed S, Dunning J. Is cryoanalgesia effective for post-thoracotomy pain? *Interact Cardiovasc Thorac Surg*. 2014;18:202–209.
6. Conacher ID. Percutaneous cryotherapy for post-thoracotomy neuralgia. *Pain*. 1986;25:227–228.
7. Connelly NR, Malik A, Madabushi L, Gibson C. Use of ultrasound-guided cryotherapy for the management of chronic pain states. *J Clin Anesth*. 2013;25:634–636.
8. Zhou L, Craig J, Parekh N. Current concepts of neurolysis and clinical applications. *J Analgesics*. 2014;2:16–22.
9. Hsu M, Stevenson FF. Wallerian degeneration and recovery of motor nerves after multiple focused cold therapies. *Muscle Nerve*. 2015;51:268–275.
10. Kim PS, Ferrante FM. Cryoanalgesia: a novel treatment for hip adductor spasticity and obturator neuralgia. *Anesthesiology*. 1998;89:534–536.
11. Mustola ST, Lempinen J, Saimanen E, Vilkko P. Efficacy of thoracic epidural analgesia with or without intercostal nerve cryoanalgesia for postthoracotomy pain. *Ann Thorac Surg*. 2011;91:869–873.
12. Ju H, Feng Y, Yang BX, Wang J. Comparison of epidural analgesia and intercostal nerve cryoanalgesia for post-thoracotomy pain control. *Eur J Pain*. 2008;12:378–384.
13. Wood GJ, Lloyd JW, Bullingham RE, Britton BJ, Finch DR. Postoperative analgesia for day-case herniorrhaphy patients. A comparison of cryoanalgesia, paravertebral blockade and oral analgesia. *Anaesthesia*. 1981;36:603–610.
14. Callesen T, Bech K, Thorup J, et al. Cryoanalgesia: effect on postherniorrhaphy pain. *Anesth Analg*. 1998;87:896–899.
15. Gwak MS, Yang M, Hahm TS, Cho HS, Cho CH, Song JG. Effect of cryoanalgesia combined with intravenous continuous analgesia in thoracotomy patients. *J Korean Med Sci*. 2004;19:74–78.
16. Robinson SR, Purdie GL. Reducing post-tonsillectomy pain with cryoanalgesia: a randomized controlled trial. *Laryngoscope*. 2000;110:1128–1131.
17. Miguel R, Hubbell D. Pain management and spirometry following thoracotomy: a prospective, randomized study of four techniques. *J Cardiothorac Vasc Anesth*. 1993;7:529–534.
18. Yang MK, Cho CH, Kim YC. The effects of cryoanalgesia combined with thoracic epidural analgesia in patients undergoing thoracotomy. *Anaesthesia*. 2004;59:1073–1077.
19. Katz J, Nelson W, Forest R, Bruce DL. Cryoanalgesia for post-thoracotomy pain. *Lancet*. 1980;1:512–513.
20. Bucerius J, Metz S, Walther T, et al. Pain is significantly reduced by cryoablation therapy in patients with lateral minithoracotomy. *Ann Thorac Surg*. 2000;70:1100–1104.
21. Dasa V, Lensing G, Parsons M, Harris J, Volaufova J, Bliss R. Percutaneous freezing of sensory nerves prior to total knee arthroplasty. *Knee*. 2016;23:523–528.
22. Hsu M, Stevenson FF. Reduction in muscular motility by selective focused cold therapy: a preclinical study. *J Neural Transm (Vienna)*. 2014;121:15–20.

Copyright © 2017 International Anesthesia Research Society. Unauthorized reproduction of this article is prohibited.
View publication stats